



Original Research Article

Retrospective study of histopathological changes in ovarian tumors

Krithik Jain N¹, C Karthipriya^{1,*}¹Dept. of Pathology, Saveetha Medical College and Hospital, Chennai, Tsmil Nadu, India

ARTICLE INFO

Article history:

Received 28-06-2019

Accepted 12-08-2019

Available online 20-09-2019

Keywords:

Benign serous cyst

Biopsy

Benign

Borderline

Malignant

Neoplasm

ABSTRACT

Introduction: Tumors of ovary are of prime importance because of its increasing occurrence and its late diagnosis due to the very vague clinical features presented by the tumor. Its occurrence starts from the thirties, and attains its peak in the seventies.

Objectives: To study the different types of ovarian tumors and its pathology and correlating it with age, sex and other important factors.

Materials and Methods: This study was done by taking 50 cases of ovarian masses which was sent to department of pathology, from the past year July 2017 – July 2018 in Saveetha Medical College and hospitals, Chennai.

Expected outcome: To find out the most prevalent type of ovarian tumor and the age group when its affected the most.

© 2019 Published by Innovative Publication.

1. Introduction

Ovarian tumors are generally more prevalent in age group of 30-65 which accounts for almost about 2/3rds of the neoplasms in that age group. Generally these tumors are hard to be detected because it has very vague clinical features. The incidence of tumors of ovaries starts from the third decade of life, and attains its peak in the 7th decade.

Among the neoplasms of the genital tract in females, the occurrence of tumors of ovary ranks second just after cervical cancer. It denotes around 30% of the total cancers occurring in female genital tract and 4 to 5% of all cancers occurring in females. There is a consistent and stable rise in the rate of cancers occurring in ovary relating to its age, comprising almost to 9% of cancers in various regions of India.

2. Materials and Methods

It is a case control retrospective study of the histopathological changes occurring in a spectrum of ovarian tumors. All

the cases related to ovarian tumors over a period of one year (from July 2017- July 2018) sent to department of Pathology for analysis were taken.

A total of 50 cases were taken which were stained by H&E stains. Detailed case history was taken, by clinical examination data and it was correlated to the histopathology patterns with age, laterality and morphological features.

3. Results

Out of the fifty cases taken from our institution, 40% of the cases were in the age group of 31-40, while there were no cases of age < 20 years. Also the age groups of 21-30 years and that of 51-60 year s had a similar incidence of cases (16%-18%). (Chart 1)

The majority of the ovarian tumor cases were benign consisting of 88%. Malignant and borderline cases were very few each consisted of 10% and 2% respectively (Chart 2).

When the laterality of the tumor was compared we found that it was dominated by right sided tumors (50%). The bilateral tumors were very few which comprised of only 6%

* Corresponding author.

E-mail address: krithikjainn@gmail.com (C. Karthipriya).

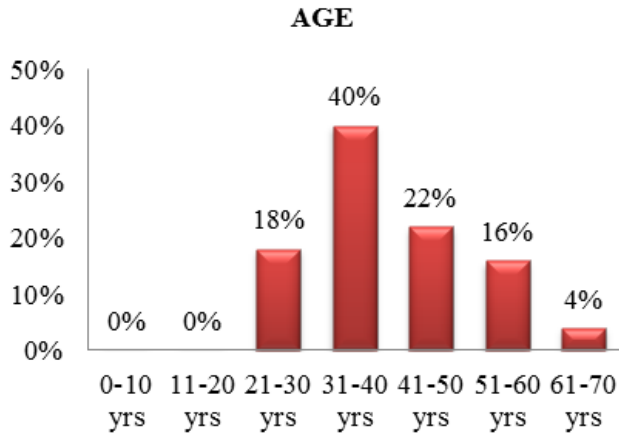


Chart 1: Age distribution chart

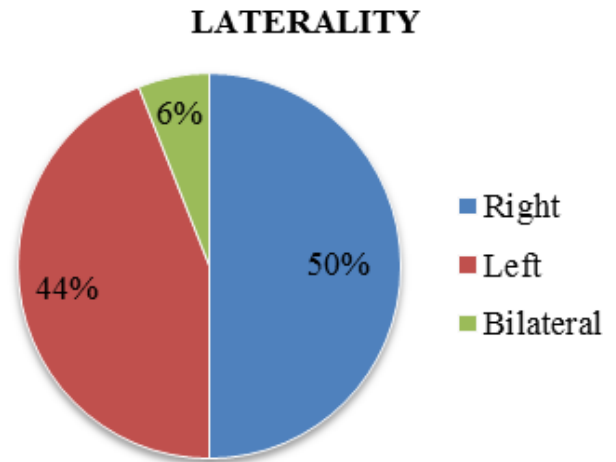


Chart 3: Laterality distribution chart

of our study.

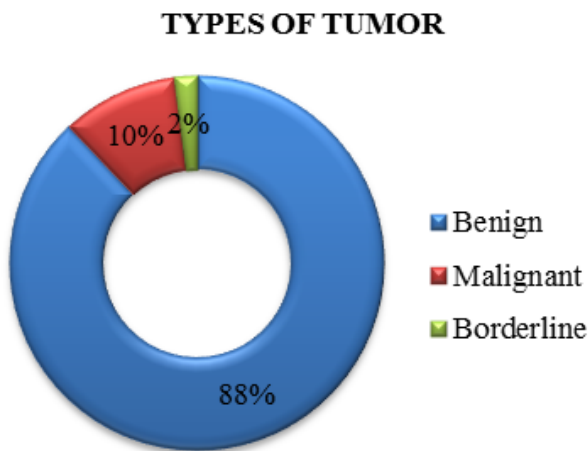


Chart 2: Types of tumor chart 1

The most common kind of ovarian mass was found to be benign serous cyst (56%) followed by benign mucinous cystadenoma (16%), and the rarest variant was mucous borderline tumor, ovarian dysgerminoma, serous borderline tumor with microinvasion comprising 2% each as seen in Chart 4. Benign ovarian fibroma and high grade serous carcinoma comprised of 10% and 8% respectively.

When we compared the most prevalent type of tumor (benign serous cyst) with that of its age predominance, it was noted that the most prevalent age group were the benign serous cyst occurred 31-40 years.

4. Discussion

In this study, out of the total 50 cases taken, 43 cases were found to be benign (86%) whereas 1 case was borderline (2%) tumor and the remaining 6 cases were malignant

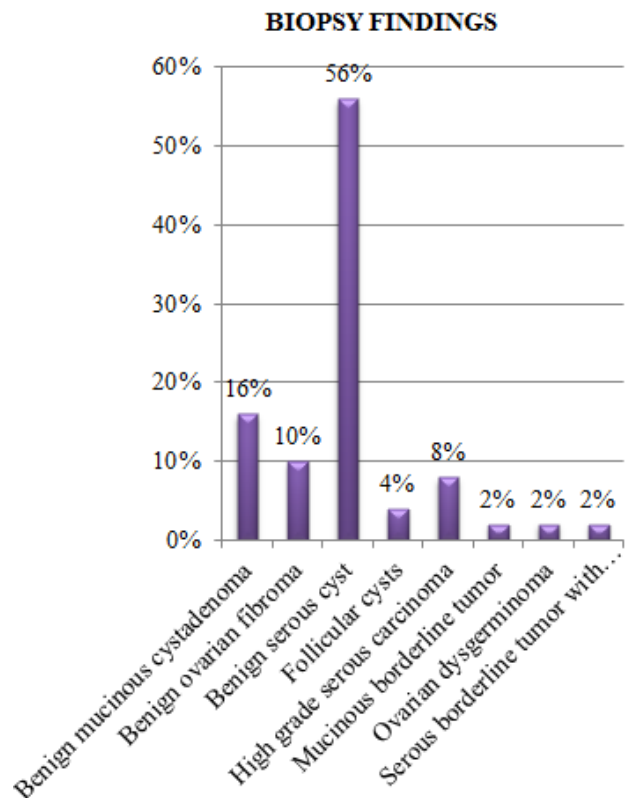


Chart 4: Histopathological finding distribution

Table 1: Occurrence of histopathological variants of neoplasm of ovary

Histopathological type	Variant	Number of patients	Percentage (%)	Bilateral
Surface Epithelial Tumors	Serous			
	Benign	28 cases	56%	1 case
	Borderline	-	-	-
	Malignant	5 cases	10%	2 cases
	Mucous			
	Benign	8 cases	16%	-
Germ cell tumor	Borderline	1 case	2%	-
	Malignant	-	-	-
	Teratoma	-	-	-
	Dysgerminoma	1 case	2%	-
Sex cord stromal tumor	Follicular cysts	2 cases	4%	-
	Fibroma	5 cases	10%	-
Others				
Total		50 cases		

Table 2: Tumor variations in a spectrum of age groups

Age Group	Benign	Borderline	Malignant	Total
21-30	8	0	1	9
31-40	20	0	0	20
41-50	8	1	2	11
51-60	5	0	3	8
61-70	2	0	0	2
Total	43	1	6	50

(12%). These findings were similar to that of Sharadha et al.¹ and Agarwal et al.² Their study results were 10 % & 18.45 for malignant, 2.2% & 3.2% for borderline and 87.8% & 78.2% for benign neoplasm respectively. Scully et al.³ noted that benign type of tumors which comprised of 75-80% were more prevalent than that of a malignant tumor. But in Maniker and Jain et al.⁴ 63.04% tumors were benign, 5.84% were borderline and 31.12% were malignant. And in Ahmad et al.⁵ 40.81%, 0.2% and 59.18% for malignant, borderline and benign tumors respectively. These studies showed a fall in the benign tumors and increase in the malignant tumor incidence.

In this study the tumors lied in the age group of mid twenties till the seventies and the tumors were predominantly noted in the 4th decade of life (40%), after which it was the fifth decade comprising of 20%. The findings of Saxena et al.⁶ were similar to our study where the average age of ovarian tumors was 32.75 years.

According to our study the general age of ovarian malignancies incidence was < 40. This finding was supported by the studies of Basic et al.⁷ and Shah et al.⁸ where there were hardly one case or no cases of ovarian malignancies under the age of 40. Except for the germ cell tumors which was predominantly found in people aged less than 30 years.

Histopathologically, Surface epithelial tumors were the most predominant variant, it comprised of 42 cases (84%)

which was, similar to that of the results of study of Sharadha et al.¹ (67%). But these findings differ from that of Monad et al.⁹ Pilli et al.¹⁰ and Jha et al.¹¹ comprising of (29.9%), (42.9%) and (32.6%) respectively. Ethnic differences were usual among tumors of ovary ; in Thanikasalam et al.¹² study, Teratomas were the most frequently occurring tumors in Chinese and Malays, while in India Serous ovarian tumors was the leading type. Now, we can also see an increase in the mucous cyst adenoma in south Indians according Sharadha et al.⁵ study.

Of the total malignant tumors serous epithelial tumors were the most prevalent comprising of 10% of total tumors occurring in ovary and there were no cases of mucous cyst adenocarcinoma found in this study. Similar observations were made by Mondal et al.⁹ Basic et al.⁷ also found that the cancers of ovary occurred mostly in the 5th decade of life but there were no cancers reported below the age of 40 years. Serous neoplasms were bilateral in 3 cases (6%) compared to no cases of mucous in our study. This was an important statistic because bilateral mucous tumor always suggests the possibility of a metastatic tumor to the ovaries from the appendix or other gastrointestinal sites, the pancreas or the endocervix, rather than a primary ovarian neoplasm.

5. Conclusion

To conclude, a number of various clinical parameters such as age of the patient, location, dimensions and histological

type of ovarian neoplasm affect the prognosis.

In all the different pathological types of tumors the most predominantly occurring variant is the benign serous type of cyst adenoma with the dominance of 56%. People belonging to fifties and sixties age group are more prone to malignancies in ovary.

6. Conflict of Interest

None.

7. Source of Funding

None.

References

1. Sharadha SO, Sridevi TA, Renukadevi TK, Gowri R, Debarman B, et al. Ovarian Masses: Changing Clinico Histopathological Trends. *J Obstet Gynecol India*. 2015;65(1):34–8.
2. Agarwal D, Kaur S, Agarwal R, Gathwal M. Histopathological Analysis of Neoplastic Lesions of the Ovary. *Int J Contemp Med Res*. 2018;5(5):77–85.
3. Scully RE, Young RH, Clement PB. Atlas of Tumour Pathology. Tumours of the ovary, maldeveloped gonads, fallopian tube, and broad ligament. In: and others, editor. Armed Force Institute of Pathology. Fascicle 23, Washington DC ; 1999., p. 1–168.
4. Mankar DV, Jain GK. Histopathological profile of ovarian tumours: A twelve-year institutional experience. *Muller J Med Sci Res*. 2015;6:107–18.
5. Ahmad Z, Kayani N, Hasan SH, Muzaffar S, Gill MS. Histological pattern of ovarian neoplasm. *J Pak Med Assoc*. 2000;50:416–25.
6. Saxena MHK, G D, Prakash P, P. Ovarian neoplasms-A retrospective study of 356 cases. *J Obstet Fynec India*. 1980;30:522–7.
7. Basic E, Kozaric H, Kozaric M, Suko A. Ovariancancer incidence and surgical approach to treatment at clinic for Gynecology and Obstetrics of Clinical Center of University of Sarajevo in 2009. *Mater Sociomed* ; 2009,.
8. Shah S, Hishikar VA. Incidence and management of ovarian tumours. *Bombay Hospital J*. 2008;50:30–3.
9. Mondal SK, Banyopadhyay R, Nag DR. Histologic pattern, bilaterality and clinical evaluation of 957 ovarian neoplasms: a 10-year study in a tertiary hospital of eastern India. *J Cancer Res Ther*. 2011;7(4):433–7.
10. Pilli GS, Suneeta KP, Dhaded AV, Yenni VV. Ovarian tumours: A study of 282 cases. *J Indian Med Assoc*. 2002;100(420):423–7.
11. Jha R, Karki S. Histological pattern of ovarian tumors and their age distribution. *Nepal Med Coll J*. 2008;10:81–5.
12. Thanikasalam K, Ho CM, Adeeb N. Pattern of ovarian tumour among Malaysian women at General Hospital, Kuala Lumpur. *Med J Malaysia*. 1992;47:139–46.

Author biography

Krithik Jain N IIInd Year MBBS Student

C Karthipriya Assistant Professor

Cite this article: Jain N K, Karthipriya C. Retrospective study of histopathological changes in ovarian tumors. *J Diagn Pathol Oncol* 2019;4(3):189-192.