

## Peripheral Ossifying Fibroma: A rare case report

Razeena Salam<sup>1,\*</sup>, Jagadish Pai<sup>2</sup>, Anish Varkey<sup>3</sup>, Amit Walvekar<sup>4</sup>

<sup>1</sup>PG Student, <sup>2</sup>Professor & Head, <sup>3</sup>Senior Lecturer, <sup>4</sup>Professor, Coorg Institute of Dental Sciences, Virajpet, Karnataka, India

**\*Corresponding Author:**

Email: nairahraz1988@gmail.com

### Abstract

Peripheral ossifying fibroma (POF) is a type of non-neoplastic gingival enlargement which shows areas of calcification or ossification. It is reactive lesion which usually arises from interdental gingiva and mostly in the anterior maxillary region. It is most commonly seen in females of second decade. The etiology can be secondary to trauma or any other local irritating factors. Differential diagnosis of POF includes pyogenic granuloma and peripheral giant cell granuloma. Careful diagnosis of peripheral ossifying fibroma is important to avoid unnecessary aggressive therapy. The definitive diagnosis is done by using histopathological examination. A conservative surgical treatment which includes the excision of lesion provides an excellent prognosis. A rare case of a 21 year old female patient with peripheral ossifying fibroma in lower front tooth region of the mouth is presented here.

**Keywords:** Gingival enlargement, Differential diagnosis, Peripheral ossifying fibroma, Pyogenic granuloma, Peripheral giant cell granuloma, Prognosis.

### Introduction

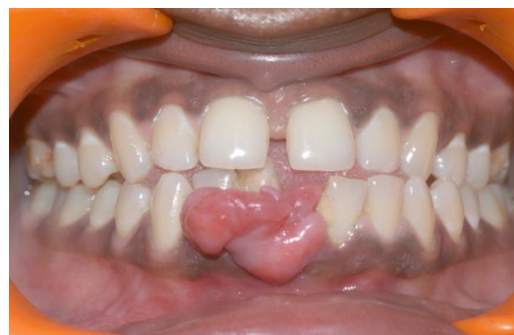Peripheral ossifying fibroma is a non-neoplastic enlargement of gingiva which is reactive in nature. It usually originates from the interdental papilla of anterior maxilla. It commonly occurs in females in 2<sup>nd</sup> and 3<sup>rd</sup> decades of life.<sup>(1)</sup> It accounts for 3.1 % of all oral tumors and 9.6% of gingival lesions.<sup>(1)</sup> The etiology of POF is unknown, however, trauma or local irritating factors can increase the chance of getting POF.<sup>(1)</sup> After the elimination of local irritating factors surgical excision of the enlargement is preferred.

A rare case report of peripheral ossifying fibroma of the anterior region of mandible is presented here.

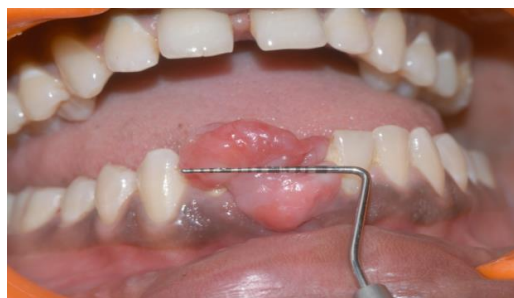### Case Report

A 21-year old female patient reported to the Department of Periodontology and Oral Implantology, Coorg Institute of Dental Sciences, Virajpet, Karnataka, with a chief complaint of swelling of the gums and mobile tooth near lower front region of the jaw since 3 years. Initially, the swelling in the lower front tooth region was small and it gradually started increasing in size in the last three years. There was no pain associated with the swelling, but the patient had discomfort during speech and while having food. There was no relevant family and medical history and patient did not give any history of trauma, injury or food impaction. On intraoral examination, a well defined pedunculated gingival growth in the interdental region between 41, 42 and 31 was observed. It involved the marginal gingiva, attached gingiva and interdental gingiva measuring about 1.5 cm × 1 cm in diameter extending from mesial aspect of 31 to 42. (Fig. 1-3)

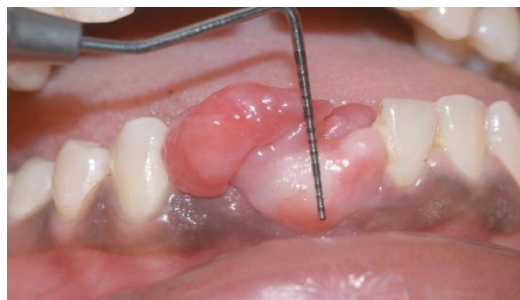Color was pale pink with smooth surfaces and well defined edges. Pathologic migration of 31 and 41 was present. On palpation, swelling was non-tender, sessile and firm in consistency.



**Fig. 1: Gingival enlargement in lower anterior region**

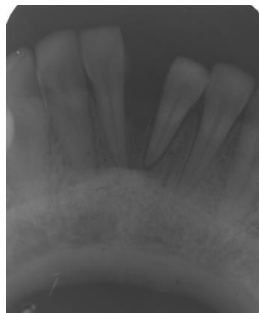


**Fig. 2: Horizontal measurement**

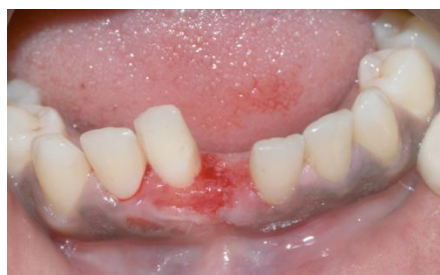

**Fig. 3: Vertical measurement**

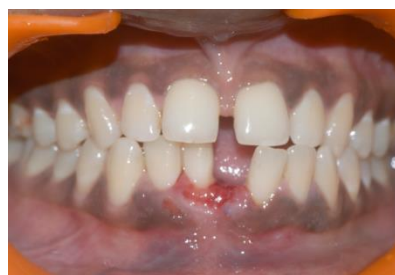Radiographic examination in the region of 31, 41 & 42 revealed the presence of irregular radiopacity evident in the mesial aspect of 31 with areas of cuffing evident in crestal region between 31& 41. (Fig. 4)



**Fig. 4: Radiographic Examination of the lesion**



**Fig. 5**



**Fig. 6**

**Fig. 5 and 6: Postoperative picture after excisional biopsy**

On the basis of clinical, histopathological, and radiographic examination, the diagnosis of POF was given. The patient presented for a follow-up examination of 10 days postoperatively. The surgical site appeared to have uneventful healing.

### Discussion

Peripheral ossifying fibroma was first described by Menzel<sup>(1)</sup> and the term was coined by Eversole and Rovin.<sup>(2)</sup> Ossifying fibroma is usually found in craniofacial bone. It is classified as central and peripheral types.<sup>(3)</sup> The central types usually originate from the endosteum or the periodontal ligament adjacent to the root apex and expand from medullary cavity of bone. The peripheral types usually of periodontal ligament origin, occurs in interdental papilla, proximity of gingiva and the periodontal ligament and shows the presence of oxytalan fibres within the mineralized matrix.<sup>(4)</sup>

In 1982, the term “peripheral ossifying fibroma” was coined by Gardner for a lesion that is reactive in nature; but is not considered to be an extrasosseous counterpart of central ossifying fibroma.<sup>(4)</sup>

The other names which had been given for peripheral ossifying fibroma includes epulis, peripheral fibroma with calcification, calcifying fibroblastic

Based on the history, clinical examination and investigations, the case was provisionally diagnosed as POF. The differential diagnosis considered were peripheral giant cell granuloma and pyogenic granuloma. Under local anesthesia, excisional biopsy was performed using scalpel (Fig. 5 and 6) and the tissue was sent to the Department of Oral Pathology for histopathological investigation.

Histologically, the tissue section showed a stratified squamous parakeratinized epithelium overlying fibrous connective tissue stroma which in deeper areas showed numerous areas of ossification. Areas of chronic inflammatory cell infiltrate and plasmocytes was also noticed.

granuloma, peripheral cementifying fibroma, peripheral fibroma with cementogenesis and peripheral cemento-ossifying fibroma.<sup>(5)</sup>

POF is a focal, reactive and non-neoplastic enlargement of gingiva. It may be found as a pedunculated or sessile enlargement with broad attachment base. The color of POF varies from red to pink. Size of most lesions ranges from 1 to 2 cm. The teeth involved usually shows pathologic migration and mobility.<sup>(4)</sup>

POF is most commonly found in females of second and third decades of life with peak prevalence between the age group of 10 to 19 years.<sup>(5)</sup> Commonly it occurs in incisor cuspid region of the maxilla. It is fairly a common lesion comprising nearly of 1% to 3%.<sup>(5)</sup>

The etiology of POF is unknown. It usually occurs due to local irritation or trauma. Orkin and Amaldas found that there is excessive proliferation of mature fibrous connective tissue in response to gingival injury or irritation.<sup>(6)</sup> It most frequently occurs in specific periods of life such as puberty and pregnancy which suggests the existence of hormonal factors in the etiology of POF.<sup>(7)</sup> Radiologically it does not show any significant changes.

Differential diagnosis include peripheral giant cell granuloma (PGCG), peripheral odontogenic fibroma and

pyogenic granuloma. The final diagnosis of POF is made by the histological investigation of biopsy specimen. PGCG contains multinuclear giant cells. Peripheral odontogenic fibroma contains odontogenic epithelium and dysplastic dentin. Pyogenic granuloma is more vascular compared with POF.

Nevoid basal cell carcinoma syndrome, Multiple endocrine neoplasia type II, neurofibromatosis and Gardner's syndrome are the syndromes associated with POF.<sup>(8)</sup>

Treatment of POF is the surgical excision of lesion with its periodontal and periosteal component. Before the excision of the lesion plaque and calculus should be removed by scaling and root planing. Recurrence rate is usually 8.9 to 20% and occurs due to incomplete removal of the lesion.<sup>(9)</sup>

### Conclusion

In the present case report, the clinical, histological and radiological features of POF with a rare case is discussed. POF is considered as one of the commonest pedunculated gingival enlargement which is clinically diagnosed as pyogenic granuloma. For the confirmation of final diagnosis of POF radiological and histopathological evaluation is needed.

### References

1. Sujatha G, Sivakumar J, Muruganandhan J, Selvakumar, Ramasamy M. Peripheral ossifying fibroma-report of a case. *Ind J Multidiscip Dent* 2012;2(1):415-8.
2. Eversole LR, Rovin S. Reactive lesions of the gingiva. *J Oral Pathol* 1972;1:30-8.
3. Miller CS, Henry RG, Damm DD. Proliferative mass found in the gingiva. *J Am Dent Assoc* 1990;121(4):559-60.
4. Yadav R, Gulati A. Peripheral ossifying fibroma. A case report. *J Oral Sci* 2009;51:151-4.
5. Bhaskar SN, Jacoway JR. Peripheral fibroma and peripheral fibroma with calcification: Report of 376 cases. *J Am Dent Assoc* 1966;73:1312-20.
6. Orkin DA, Amaldas VD. Ossifying fibrous epulis—an abbreviated case report. *Oral Surg Oral Med Oral Pathol* 1984;57(2):147-8.
7. Kenney JN, Kaugars GE, Abbey LM. Comparison between the peripheral ossifying fibroma and peripheral odontogenic fibroma. *J Oral Maxillofac Surg* 1989;47(4):378-82.
8. Sudhakar S, Kumar B, Prabhat MPV. Peripheral Ossifying Fibroma. *J Health Allied Scs* 2009;8:17.
9. Shah M, Rathod CV, Shah V. Peripheral ossifying fibroma – a rare type of gingival overgrowth. *J Indian Soc Periodontol* 2012;16(2):275-7.