

Preoperative Magnetic Resonance evaluation of perineal endometriosis in episiotomy scar with anal sphincter involvement

Vijaya Rajesh Kamble^{1,*}, Madhuri Sushil Gawande²

¹Associate Professor, ²Assistant Professor, NKP Salve Institute of Medical Sciences & Research Centre, Nagpur

***Corresponding Author:**

Email: vijayashelkar@gmail.com

Abstract

Perineal endometriosis in episiotomy scar with anal sphincter involvement is an infrequent occurrence. After six months follow-up, there were no complications reported by faecal incontinence. Endometriosis is defined as the presence of ectopic functional endometrial tissue outside the uterine cavity. Clinically scar endometriosis presents as a palpable subcutaneous mass near surgical scars associated with cyclic pain and swelling during menses. Local examination is essential for an accurate diagnosis. Here we present a case with perineal endometriosis in episiotomy scar with involvement of external anal sphincter and puborectalis muscle treated with wide surgical excision. Magnetic resonance imaging has given detailed extension of the lesion with the help of which wide excision of endometriotic tissue was possible. During surgery care was taken to remove all affected tissue. The recovery was uneventful with excellent functional and aesthetic results. On follow up after six months of operation, woman was found to be asymptomatic.

Keywords: Episiotomy scar, Endometriosis, Magnetic resonance imaging.

Introduction

Scar endometriosis in the perineal region is a rare condition affecting young females at the episiotomy site following a previous vaginal delivery. Endometriosis is reported in 15% to 44% of women who undergo laparoscopy or laparotomy and are of reproductive age.⁽¹⁾ Endometriosis is commonly found in the pelvis and seen in the ovaries, uterosacral ligaments and round ligaments. Extrapelvic sites are bladder, gastrointestinal tract, lungs and on skin especially after obstetric surgical interventions⁽²⁾ such as in the perineum following vaginal delivery with episiotomy, in abdominal surgery scar areas following hysterectomy and caesarean sections.

Several theories have been proposed in aetiology of scar endometriosis. But the more widely followed theory is being direct implantation of the endometrial tissue in scars during various surgical procedures.⁽³⁾ The knowledge of the clinical background of the diseases is essential for scar endometriosis.

In this case report, we present a case of extrapelvic perineal endometriosis in an episiotomy scar. Diagnostic tools used included Magnetic Resonance Imaging (MRI) and biopsy.

Case History

A 38-year-old woman with pain and swelling in right side of perineal region since 2-3 years was referred to our department. Her pain was cyclical initially and later on it was present throughout and more during menses. Swelling appeared approximately two years back and increased in size gradually to the present size of 3 cm x 3 cm. She described her pain as severe, preventing her from performing ordinary daily activities. Her medical history was significant due to

previous pregnancy with vaginal delivery requiring episiotomy. On local examination, a tender mass of 3 cm x 3 cm was noted on right side of anus. The mass was hard in consistency with irregular margins. Skin over the mass was pigmented and puckered. This mass was intimately associated to the episiotomy scar. On digital examination, rectal mucosa was free. Patient had a good sphincter squeeze tone and a good resting tone at digital rectal examination. MRI examination of the perineum was indicated. MRI revealed a relatively well defined area in the perineal region on right side. This area was iso-intense to muscle on T1Weighted Imaging (Fig. 1a).

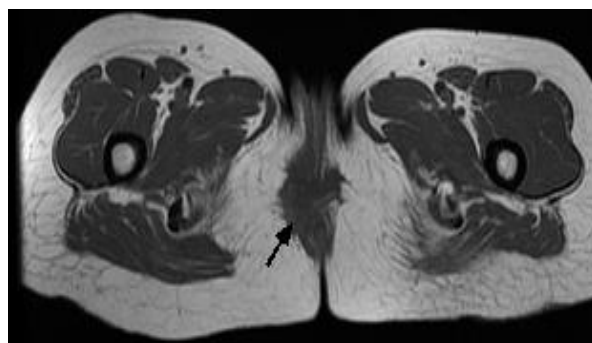


Fig. 1a: Axial T1WI of perineum shows relatively well defined area (black arrow) iso-intense to muscle

On T2Weighted Imaging it is relatively hyperintense to muscle (Fig. 1b).

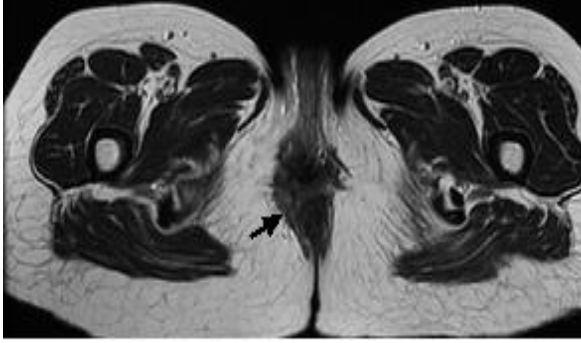


Fig. 1b: On Axial T2WI, this relatively well defined area is hyperintense to muscle (Black arrow)

The lesion measured approximately 2 cm x 3.1 cm in transverse and anteroposterior dimensions respectively and extended craniocaudally for a distance of 3.6 cm. The lesion showed radiating, irregular margins with peripheral strands radiating from the lesion. On gadolinium contrast enhanced T1-Weighted fat - suppressed study, the lesion shows marked enhancement (Fig. 1c).

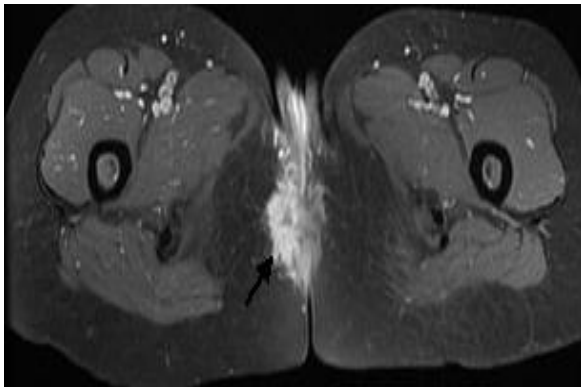


Fig. 1c: Gadolinium contrast enhanced T1weighted fat suppressed axial image shows marked enhancement of the lesion (arrow)

Also involvement of right sided external anal sphincter, puborectalis muscle and few fibres of levator ani muscle are shown by MRI (Fig. 2).

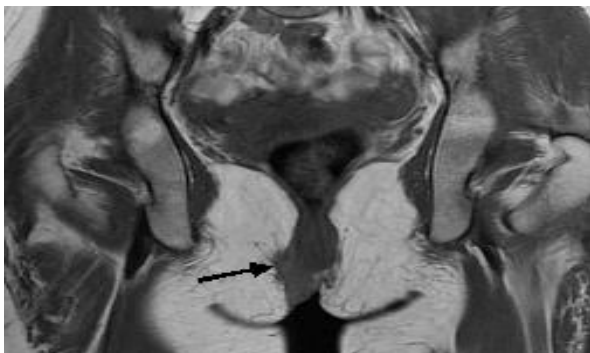


Fig. 2: Coronal T1WI shows involvement of external anal sphincter, puborectalis muscle and few fibres of levator ani

On MRI, diagnosis of endometriosis in episiotomy scar with anal sphincter involvement was given. Lesion was excised with 1 cm of healthy margin and 3 cm x 3 cm of fibrotic mass was excised. Intraoperatively, it was found that the mass was involving external anal sphincter and puborectalis muscle. These findings were consistent with MR imaging. External anal sphincter was reconstructed. Histopathological examination revealed the features of endometriosis. It showed endometrial glands with stroma, blood and hemosiderin macrophages (Fig. 3).

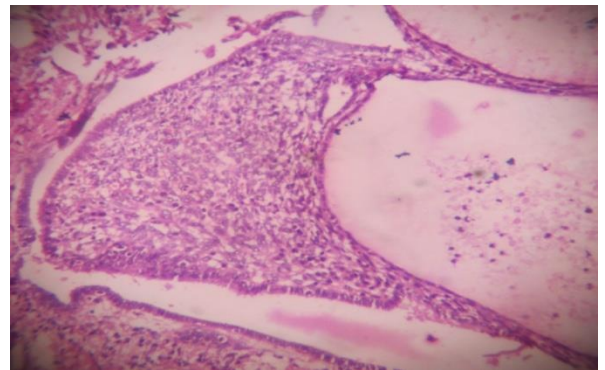


Fig. 3: Photomicrograph (original magnification, X 100; haematoxylin-eosin stain) shows endometrial glands and typical stroma, blood and hemosiderin macrophages

On follow-up of six months, the patient was totally relieved of symptoms. The postoperative course has no complications. The patient was asymptomatic without any signs of recurrence after six months follow up of surgery and has good functional results (better resting and squeeze tone).

Discussion

Schickele et al⁽⁴⁾ in 1923 reported the first case of endometriosis with perineal involvement. Few studies have suggested 0.06-0.7% incidence of endometriosis in episiotomy region after normal vaginal delivery.⁽⁵⁾ Endometriosis is associated with pelvic pain, dyspareunia and dysmenorrhoea, may be asymptomatic or cause symptoms related to inflammation, obstruction or bleeding. The incidence of endometriosis occurs between 30 and 40 years of age⁽⁶⁾ as it is in our case. The latent period between surgery and symptoms in our case is 10 to 12 years. A high index of suspicion is required since a large number of patients do not meet the classic triad of mass, cyclic pain and previous incision. Almost half of the patients present with non-cyclic pain.⁽⁷⁻⁸⁾ In our case the pain was initially cyclic but eventually became almost non cyclic.

The perineal endometrioma with affection of anal sphincter appears after the episiotomy or laceration during childbirth. The scar of episiotomy is a site of occurrence of endometriosis and the affection of anal sphincter occurs infrequently.⁽⁹⁾ The pathogenesis of scar endometriosis may be explained by the direct implantation of endometrial cells following vaginal delivery, somehow similar to that of endometriosis developing in caesarean scars. Clinical history is crucial in the diagnosis and choice of management.⁽³⁾ MR imaging features on T1 and T2 Weighted imaging and on post contrast gadolinium study are almost same as in previous studies.⁽¹⁰⁾ MRI allows and makes easier and appropriate surgical procedure and provides perineal endometriosis patients with a good clinical outcome.⁽¹¹⁻¹²⁾ The extent and biologic behaviour can be further evaluated by MR imaging.⁽¹³⁾ The objective is to excise the endometrioma completely, which may compromise the anal sphincter.

MR imaging in our case confirmed the clinical diagnosis of scar endometriosis as well as told the precise extent of the scar endometrioma. According to the literature and our own experience precise extension of endometriotic tissue revealed with MRI, wide excision of endometriotic tissue seems to be the best chance of cure with satisfactory functional results and should be recommended. In our case due to precise extension shown by MRI, excision of the lesion with external anal sphincter reconstruction was possible.

Conclusion

In conclusion, use of diagnostic MR imaging in the preoperative assessment of scar endometriosis with anal sphincter involvement is very helpful for accurate determination of the extent of the disease. Due to this approach total surgical excision is possible with avoidance of disease recurrence.

References

1. Blanco RG, Parthivel VS, Shah AK, Gumbs MA, Schein M, Gerst PH. Abdominal wall endometriomas. *American J Surg* 2003;185(6):596-598.
2. Francica G, Giardiello C, Angelone G, Cristiano S, Finelli R, Tramontano G. Abdominal wall endometriomas near caesarean delivery scars: sonographic and color Doppler findings in a series of 12 patients. *Journal of Ultrasound in Medicine* 2003;22(10):1041-1047.
3. Gunes M, Kayikcioglu F, Ozturkoglu E, Haberal A. Incisional endometriosis after caesarean section, episiotomy and other gynaecologic procedures. *Journal of Obstetrics and Gynaecology Research*.2005;31(5):471-475.
4. Schickele M. Les pseudolipomes du ligament large. *Bull Mem Soc Anat Paris* 1923;20:603-605.
5. Nominato NS, Prates LFVS, Lauer I, Morais J, Maia L, Geber S. Scar endometriosis: a retrospective study of 72 patients. *Revista Brasileira de Ginecologia e Obstetricia* 2007;29(8):423-427.
6. Puerta JD, Castano R, Hoyos S. Endometrioma de esfinter anal. *Rev Colombiana Cir* 1999;14:243-246.
7. Singh KK, Lessells AM, Adam DJ, Jordan C, Miles WF, Macintyre IM, et al. Presentation of endometriosis to general surgeons: a 10 years experience. *Br J Surg* 1995;82(10):1349-51.
8. Frilas A, Soi A, Max M. Abdominal incision endometriosis. *Am Surg* 1954;60:259-61.
9. Sayfan J, Benosh L, Segal M. Endometriosis in episiotomy scar with anal sphincter involvement- Report of a case. *Dis Colon Rectum* 1991;34:713-716.
10. Gidwaney R, Badler RL, Yam BL, Hines JJ, Alexeeva V, Donovan V, et al. Endometriosis of abdominal and pelvic wall scars: Multimodality imaging findings. *Pathologic Correlation and Radiologic Mimics. Radiographics* 2012;32:2031-2043.
11. Teh J, Leung J, Dhar S, Athanasou NA. Case report - Abdominal wall endometriosis: Comparative imaging on power Doppler ultrasound and MRI. *Clinical Radiology Extra* 2004;59:74-77.
12. Pados G, Tympanidis J, Zafrakas M, Athanatos D, Bontis JN. Ultrasound and MR -imaging in preoperative evaluation of two rare cases of scar endometriosis. *Cases Journal* 2008;1(1):97.
13. Odobasic. A, Pasic A, Latifagic EI, Arnautalic L, Odobasic Ad, Idrizovic E, et al. Perineal endometriosis: a case report and review of the literature. *Techniques in Coloproctology* 2010;14(1):25-27.